

# Silicosis\*

## A Study of 106 Pottery Workers

PAUL A. QUAINANCE, M.D.

*Associate Medical Director, Golden State Hospital, Los Angeles, Calif.*

**P**NEMOCONIOSIS, a "disease due to breathing air containing silica ( $\text{SiO}_2$ ) is characterized anatomically by generalized fibrotic changes and miliary nodulation in both lungs, clinically by shortness of breath, decreased chest expansion, lessened capacity for work, increased susceptibility to tuberculosis,"<sup>1</sup> and roentgenographically by diffuse nodular or confluent pulmonary shadows, increase in peribronchial and hilar densities and decreased excursion of the diaphragm.

### INCIDENCE

Hippocrates described the breathing difficulty of metal-diggers. Agricola,<sup>2</sup> in 1557, wrote: "When the dust is very corrosive it ulcerates the lungs and produces consumption. Hence it is that in the Carpathian Mountains there are women who have married 7 husbands, all of whom this dreadful disease has brought to an early grave." Löhneiss,<sup>2</sup> in 1690, recorded that "... the dust and stone fall upon the lungs, the men have lung disease, breathe with difficulty, and at last have consumption." Ramazzini<sup>3</sup> first described the grating sound produced by cutting the lung tissues of stone and

coal workers early in the 18th century.

Although observed in every industry where silica-laden air is encountered, pneumoconiosis was not scheduled as a compensable occupational disease until 1910 when New Zealand included it under the Workmen's Compensation Act and almost immediately rescinded the action (Sayers<sup>2</sup>). Interstitial pneumonia, or miners' phthisis, was recognized among the zinc and lead miners of Utah and Nevada in the same year. It had been known in the Transvaal in 1899. Today silicosis ranks with the dermatitides as one of the most important occupational diseases which McCord<sup>4</sup> aptly has termed "Medicine's Unclaimed Province." It is estimated by Lanza and Vane<sup>5</sup> that in the United States fully  $\frac{1}{2}$  million workers are exposed to silica dust in the chief mining, quarrying, rock-drilling, clay products, and associated manufacturing industries. Pneumatic tools and natural stone grinding wheels have made silicosis world-wide.<sup>6</sup>

An acute form of the disease occurs with symptoms manifested as early as 3 years after initial exposure to mixtures of silica and soap alkalis. Such cases have been described in soap powder grinders and packers by Chapman<sup>7</sup> and MacDonald,<sup>7</sup> in scouring powder workers by Kilgore,<sup>9</sup> in sand blasters by Foord,<sup>10</sup> and others, and in lens grinders by Russell.<sup>11</sup> Death usually is from terminal pneumonia or tuberculosis.

\* Read before the Industrial Hygiene Section of the American Public Health Association at the Sixty-third Annual Meeting in Pasadena, Calif., September 5, 1934. Read (in part) before the Industrial Medicine and Surgery Section of the California Medical Association at the sixty-second annual session, Del Monte, April 24-27, 1933.

A more gradual development of silicosis was found by Clark<sup>12</sup> in two-thirds of a group of carborundum and carbide workers with average occupation period of 10 years. Lawson, Jackson and Gardner<sup>13</sup> found 9 of 17 iron miners with exposure of 3 to 8 years, to have died during the following 21 years. The remainder showed rapidly progressing fibrosis. Lanza<sup>14</sup> reported the average age at death of zinc miners in Missouri as 36 years and the life expectancy of iron ore workers as 9.6 years. In 1900 Murray reported an asbestos worker who was the only living survivor of 11 men entering that industry 10 years previously. Asbestos dust enters the lungs as a silicate rather than as the oxide of silica.

Characteristically pneumoconiosis develops insidiously and symptoms are latent. Thus Britton and Head<sup>15</sup> saw a granite worker and a knife grinder each with only 4 months exposure who first developed symptoms 23 and 14 years later respectively.

In a comprehensive review, Pancoast and Pendergrass<sup>16</sup> found fibrosis in 74 per cent of 495 sandstone workers, and in 57 per cent of 208 rock drillers with average exposure of 21 years. Fifteen per cent of those affected had third stage silicosis. Fifteen of 20 cement plant workers exposed over 7 years had slight fibrosis. Orr<sup>16</sup> reported second stage silicosis in a buck-and-wing dancer who for 25 years had scattered sand on the stage before each performance. Mills<sup>18</sup> found advanced fibrosis at autopsy on a man who had worked in an asbestos mine 32 years previously for a short period only. In hard coal miners with average exposure of 11 years, Tattersall<sup>19</sup> found silicosis developing slowly and insidiously. In Welsh coal miners after 20 years' service, Cummins<sup>20</sup> found the lungs to contain large amounts of both rock and coal dust. In his experience silicosis appeared long before tuberculosis de-

veloped and coal miners were not very susceptible to the latter. McFarland,<sup>21</sup> and Russell, *et al.*,<sup>22</sup> found silicosis to be almost universal in granite workers (Barre, Vt.) with an unusual susceptibility to tuberculosis after 20 years' exposure. Head and Rosenblum<sup>23</sup> found 3.7 per cent of 500 males admitted consecutively to Cook County Tuberculosis Hospital to have tuberculo-silicosis.

#### PATHOGENESIS AND PATHOLOGY

The crystalline and amorphous silica compounds ( $\text{SiO}_2$ ) comprising rock crystal, quartz, quartzite, flint and sandstone, are the chief producers of silicosis. Lemon and Higgins<sup>24</sup> emphasize the point that more than 10 million particles of silica per cu. ft. of air and a size of less than 10 microns are essential to any appreciable silicosis hazard. As high as 92 million particles have been determined.

Many observers (Belt,<sup>25</sup> Lemon and Higgins,<sup>24</sup> Russell,<sup>22</sup> Mavrogordato,<sup>16</sup> Pancoast and Pendergrass,<sup>16</sup> *et al.*) believe that following inhalation the particles of silica are engulfed by macrophages or "dust cells" which enter and block the lymph spaces. Mavrogordato<sup>16</sup> concludes that silica kills the "dust cells" and dissolves in the alkaline tissue juices forming a poisonous hydrosol jelly ( $\text{Si}(\text{OH})_4$ ). Gye and Kettle<sup>26</sup> have shown experimentally that colloidal silica when injected into animals is poisonous. Fibroblastosis is stimulated and a fibrotic nodule is formed about the dead macrophages. The center of the nodule heals and is free from silica; the periphery grows and abounds in silica particles. Confluence of these nodules produces a massive fibrosis in which are found nests of silica with contiguous healed lesions some of which show 1 mm. or less areas of degeneration. Few believe, with Arntzen,<sup>26</sup> that the physical characteristics (sharp edges) of the silica

particles are of much importance, although the presence of alkalis, concomitant infections, and rapid breathing undoubtedly predispose to silicosis.

McNally<sup>27</sup> reminds us that silica is a normal constituent of the human body but concludes that any lung containing more than 2 mg. of  $\text{SiO}_2$  per gm. has had undue exposure to a dusty atmosphere. He found an average of 1.13 mg. of silica per gm. of dry lung in 21 samples from non-silicotic persons and reported from 2.4 to 26.0 mg. of  $\text{SiO}_2$  per gm. of dried lung in workers in various dusty trades. Stone and granite cutters showed the higher amounts. Church<sup>27</sup> found the ash of potters' lungs to contain 47.78 per cent silica. In a study of 15 tunnel rock drillers and sand blasters and pulverizers, 12 of whom died of pulmonary infections within 9 to 18 months after short exposures, Gardner<sup>28</sup> found almost universally (all but one) microscopic but not gross evidence of silicosis. Sixty-one per cent of the bronchial lymph nodes were silicotic. The nodules ranged from 0.3 to 0.4 mm. in diameter as compared with 3.0 to 4.0 mm. sizes found in hard rock and lead miners with many years' exposure. A maximum of 3.1 per cent silica content in the lungs was found.

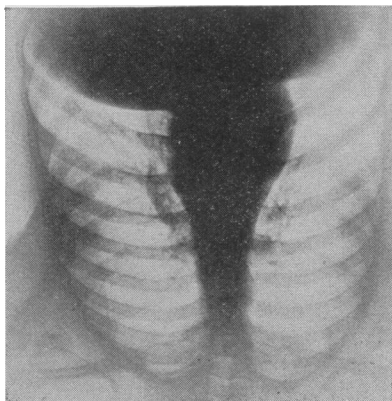
#### SYMPTOMS

As Russell<sup>22</sup> points out, dyspnea, the earliest and the cardinal symptom, first sets in years after initial exposure and is progressive for years after exposure ceases. By the time shortness of breath is complained of, fibrosis already is moderately advanced, diminution in expansion and decrease in fremitus and resonance are demonstrable, and usually there is unproductive cough. Later the harsh breath sounds at the bases of the lungs become almost inaudible. Vital capacity is reduced. Cyanosis may be present. The anteroposterior diameter of the chest may be increased an inch.

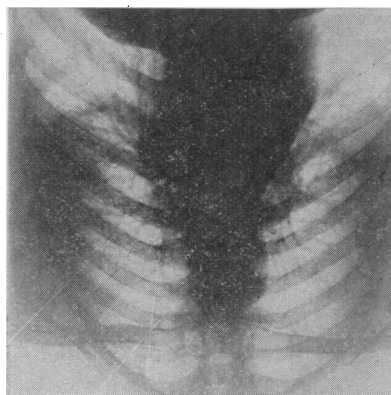
The patient, however, remains well nourished unless tuberculosis complicates the picture.

The earliest roentgenographic findings are increased density of the hilus shadows and trunk branches, perhaps indistinguishable from the changes resulting from repeated respiratory tract infections. A diffuse increase in linear markings follows and in second stage fibrosis nodulation, most pronounced in the central and basal fields, is observed. Confluence of these nodules produces a picture of consolidation in third stage fibrosis in which pleural adhesions also are almost constant. An important prognostic sign is the fluoroscopic observation of limited excursion of the diaphragm.<sup>16</sup>

In the differential diagnosis it must be remembered that other dusts than silica, as well as other diseases, produce changes in the structure of the lungs, as pointed out by Pancoast and Pendergrass.<sup>29</sup> The writer has observed 1 case of advanced fibrosis of the lungs in a laborer who for 10 years had cleaned soot and lamp black from the stand pipes and gas purifier of a gas plant. The size of the heart shadow and the prompt disappearance of the lung shadows with restored compensation betray the passive congestion of cardiac decompensation and coronary thrombosis. In bronchiectasis the cough is not unproductive, and dilated bronchial shadows are disclosed by roentgenograms. In the asthmatic chest the mottling is accentuated during and immediately after attacks. Metastatic mycotic infections closely simulate the nodular phase of silicosis but isolation of the fungus and the clinical signs clear up the diagnosis. Diagnosis oftentimes will have to depend on post-mortem determination of the silica content of the lung tissues and the presence or absence of the ulceration and progressive destruction characteristic of tuberculosis.<sup>30</sup>



*Case 35*—R. S., age 17 years, a caster for 3 years, had negative history and normal physical findings. X-rays (Plate I) revealed only slight peribronchial thickening and increased density in the hilar regions.



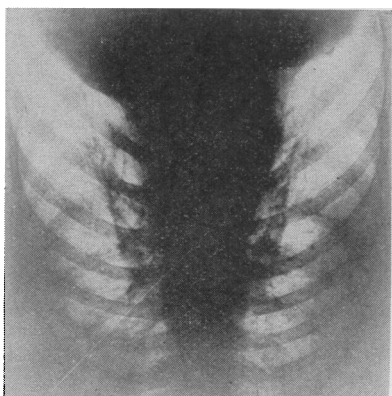
*Case 54*—M. P., age 32 years, a caster for 6 years, and coal miner for 10 years, had influenza 4 years previously, presented no symptoms and only slightly impaired resonance in the interscapular regions. X-rays (Plate II) showed moderate fibrosis, with diffuse peribronchial thickening and increased density of the hilar and perihilar areas.

#### REPORT OF STUDY

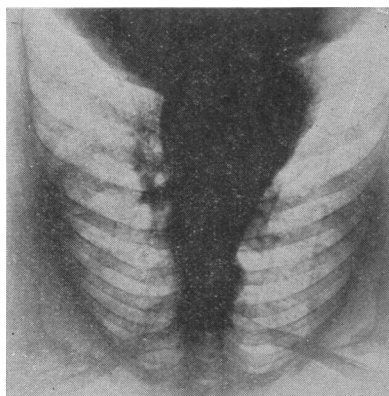
In the plant studied, bathroom ware exclusively is manufactured. The clay mixture contains 20 per cent silica, 26 per cent feldspar, 27 per cent English china clay, 10 per cent domestic china clay, 11 per cent English ball clay, and 6 per cent finely ground pitcher or broken ware. The free silica content approximates 20–25 per cent.

The casting room constitutes the essential dust hazard. Each caster must shake silica dust into, and dry-sand-paper and brush off the dust from his

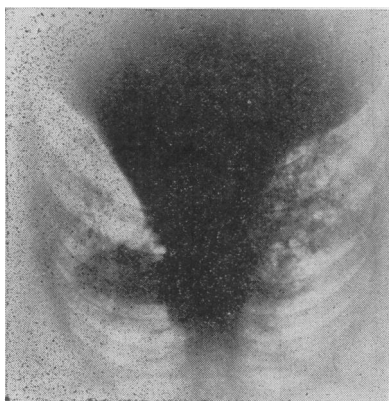
own moulds. He is constantly inhaling silica dust and wears no mask. Occasionally the floor is sprinkled with water. There is no forced ventilation system. The fine dust which settles on the moulds while on the drying rack is blown off with a compressed air hose before the moulds go to the kilns. The dust produced by crushing and regrinding the ware broken during the first



*Case 17*—J. G., age 42 years, a caster for 10 years, had a negative history, symptoms and physical findings. X-rays (Plate III) revealed moderately advanced nodular fibrosis of the upper two-thirds of the lungs with dense hilar, perihilar and lower peribronchial shadows and diaphragmatic adhesions.



*Case 34*—J. S., age 48 years, a presser and caster for 27 years, had negative history, no symptoms, and had avoided inhaling dust when possible. Harsh breath sounds posteriorly, and a few coarse basal râles were heard. Fluoroscopy showed diaphragmatic adhesions. X-rays (Plate IV) revealed marked diffuse nodular fibrosis, with early massive confluence of the perihilar nodules.

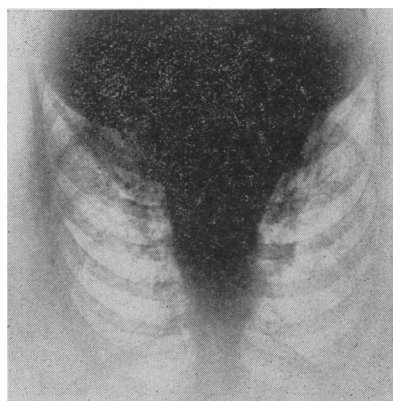

*Case 56*—D. P., age 54 years, a potter for 21 years, had influenza 12, and right basal pleuritis 7 years previously. He had complained for 5 years of progressive shortness of breath and weakness, for 1½ years of dry cough, and for 2 weeks of inability to work as a foreman because of "smothering spells" (dyspnea), on the least exertion. He had lost 20 pounds in 2 years. Expansion of the chest was decreased; resonance was impaired in the interscapular and basal regions where dry coarse râles were heard. Breath sounds, harsh throughout, were distant at the bases. Fluoroscopy showed restricted excursion of the diaphragm. X-rays (Plate V) revealed advanced nodular fibrosis with massive confluence in the central and right basal fields.

This patient was awarded total and permanent disability pension by the Industrial Accident Commission of California.

firing, constitutes an additional hazard.

One hundred and six employees, exclusive of the office workers, were examined physically. In 58, with an average duration of exposure to silica-laden air of 7½ years, X-rays of the



*Case 25*—H. G., age 43 years, a caster for 12 years, had negative history, no symptoms or abnormal physical findings. X-rays (Plate VI) revealed marked diffuse nodular fibrosis with early massive confluence in the perihilar and inner basal fields. Death occurred 3 months later from respiratory failure 2 days after catching cold at his work. At autopsy were found healed apical (tuberculous) scars, dense, pleural adhesions, streaks of scar tissue scattered throughout both lungs, several small abscesses in the base of the left upper lobe, and scattered small bronchopneumonic consolidations.

chest were taken. As indicated in Table I, 5, or 8.6 per cent, showed third stage or advanced fibrosis, the average duration of exposure being 16 years. Twenty-two, or 38 per cent, had second stage or moderate fibrosis. The remaining 31, or 53.4 per cent, showed only slight fibrosis. In 5 of these latter the changes were confined principally to the hila.

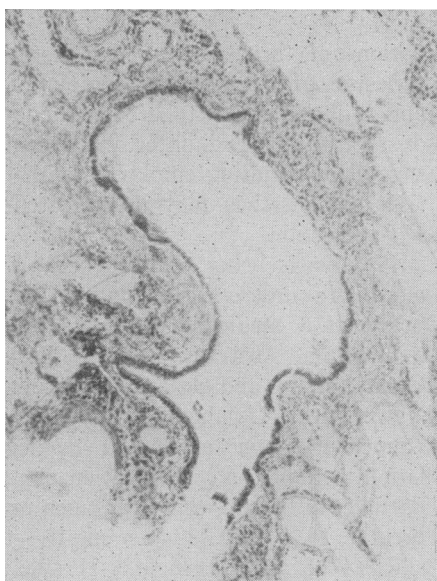
TABLE I

## PNEUMOCONIOSIS (SILICOSIS)

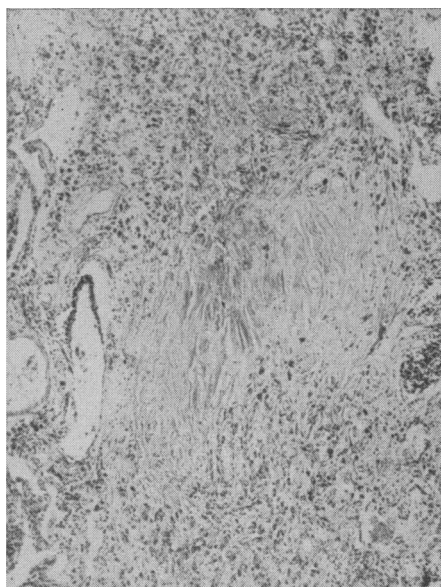
Incidence in 58 of 106 Pottery Workers as Determined by X-rays of the Lungs  
(Quaintance-Morris)

Stage of Silicosis			Number	Per cent
Third *	Markedly advanced	3	5	8.6
	Moderately advanced	2		
Second	Moderate	22	22	38.0
First	Slight	26	31	53.4
	Hilus only	5		
Total			58	100.0

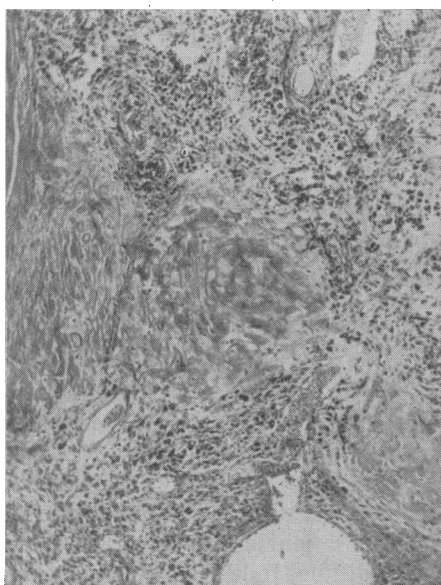
\* Average duration of exposure was 16 years in advanced group.



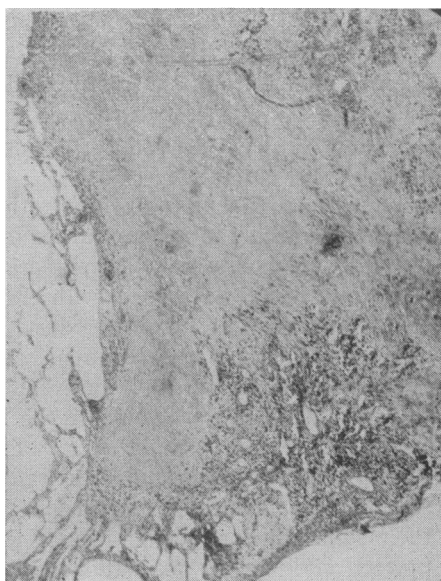
*Case 25*—Early peribronchial fibrosis with siliceous deposits at outer margin. Plate VII.



*Case 25*—Early nodular fibrosis with many fibroblasts and silica particles at periphery. Plate VIII.



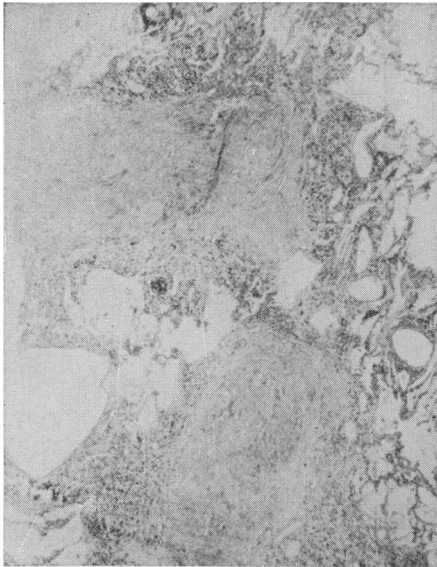
*Case 25*—Advanced silicotic nodules with beginning massive fibrosis. Note heavy peripheral siliceous deposits. Plate IX.



*Case 25*—Advanced, nodular silicosis, with marginal emphysema. Note sparsity of silica particles. Plate X.

Pancoast and Pendergrass<sup>16</sup> in a study of 58 potters, reported third stage silicosis in 36 per cent, second stage changes in 48 per cent and first stage

silicosis in only 16 per cent. The average duration of exposure to dust in their series was not given, hence no accurate comparisons can be made.



Case 25—Contiguous, advanced silicotic nodules, with adjacent atelectasis and emphysema. Note absence of siliceous deposits. Plate XI.

#### TREATMENT

Since the nature of silicosis precludes the possibility of arrest of the progressive fibrosis it is obvious that our efforts must be directed at prevention:

First, reduction of the concentration of silica dust in the inspired air is imperative. Adequate exhaust ventilation equipment will replace dusty with clean air. Wetting will eliminate dust in grinding and mining operations and settle the dust in blasting rooms before workers enter. Chilled iron shot can be substituted for sand in blasting. Enforced wearing of adequate respirators and helmets and proper provision for their supervision and maintenance will protect workmen in occupations where wetting is not feasible.

Second, selective employment will result in the transfer of the unfit to less hazardous occupations. Preemployment examinations, including careful occupational history and record of past diseases, complete physical examination and X-rays of the chest, will make possible exclusion from hazardous occu-

pations of those having had excessive exposure to silica dust (Sappington<sup>31</sup>) and will keep the tuberculous out of dusty trades. Todhunter and Dixon<sup>32</sup> suggest acquainting employees with the risks so that they may be educated in self-protection.

Progress is being made. Preemployment and interval examinations by a board of 3 medical examiners are required in Australia, South Africa, Great Britain, and Ontario. Wisconsin, New York, Oklahoma, and Ontario (Sayers<sup>33</sup>) have attempted by legislation to limit the concentration of dust particles in the air which workmen must breathe to 10,000,000 per cu. ft.—the silicosis hazard threshold. If silicosis is to be controlled employers must be convinced that these preventive measures not only protect the health of their employees but are economically sound policies from the standpoint of industry.

#### COMPENSABILITY

Pneumoconiosis is regarded universally as an occupational disease. It is recognized as cause for total and permanent disability pension. In California under recent decisions of the Appellate Court with concurrence of opinion by the Supreme Court, the "date of injury" with respect to operation of the "statute of limitations" is regarded as the time of onset of symptoms or that time when the presence of silicosis could reasonably have been determined by medical examination of the applicant. Where more than one compensation insurance carrier is concerned, the Industrial Accident Commission has been ordered to apportion the liability for compensation as the duration of employment or the periods of insurance coverage would indicate as being equitable.

#### SUMMARY AND CONCLUSIONS

1. Inhalation of silica laden air results in pneumoconiosis, a progressive, incurable occupational disease of the lungs.

2. Fifty-eight cases are reported from the pottery industry in which the concentration of dust is low, silicosis develops slowly, symptoms are latent and appear many years after physical and X-ray signs of silicosis are demonstrable.

3. In advanced silicosis total and permanent disability for work, and a high susceptibility to pneumonia and tuberculosis are being recognized by the Industrial Accident Boards. Tuberculosis was not observed clinically in the group studied; pneumonia terminated 1 case.

4. Prevention of inhalation and reduction in concentration of silica laden air must receive more attention from the industries concerned, state legislatures and the medical profession if silicosis is to be controlled.

## REFERENCES

- 1, 2. Sayers, R. R. Pneumoconiosis—Silicosis. *Pub. Health Rep.*, 49:595-603 (May 18), 1934.
3. Henderson, Fergus S. Silicosis. *Edinburg Med. J.*, 36:166-170 (Mar.), 1929.
4. McCord, Carey P. Occupational Diseases—Medicine's Unclaimed Province. *Surg., Gyn., Obs.*, 56:547 (Feb.), 1933.
5. Lanza, A. J., and Vance, Robert J. Pneumoconiosis—Prevalence of Silicosis in General Population and Its Effects Upon Incidence of Tuberculosis. *Am. Rev. Tuberc.*, 29:8-16 (Jan.), 1934.
6. Lanza, A. J. Etiology of Silicosis. *J.A.M.A.*, 101:583-584 (Aug. 19), 1933.
7. Chapman, Earle M. Pneumoconiosis—Acute Silicosis. *J.A.M.A.*, 98:1439-1441 (Apr. 23), 1932.
9. Kilgore, E. S. Pneumoconiosis, Unusually acute form. *J.A.M.A.*, 99:1414-1416 (Oct. 22), 1932.
10. Foord, A. G. Personal Communication.
11. Russell (see 22).
12. Clark, W. Irving. *The Dust Hazard in the Abrasive Industry*.
13. Lawson, G. B., Jackson, W. P., and Gardner, J. E. Pneumoconiosis in Iron Miners. *J.A.M.A.*, 96:1129-1131 (Apr. 4), 1931.
14. Lanza and Higgins. Status of Silicosis. *A.J.P.H.*, 19:635-640 (Jan.), 1929.
15. Britton, J. A., and Head, J. R. Pneumoconiosis—The Delayed Development of Symptoms. *J.A.M.A.*, 96:1938-1939 (June 6), 1931.
16. Pancoast, H. K., and Pendergrass, E. P. Pneumoconiosis Review; Further Roentgenological and Pathological Studies. *Am. J. Roentgen.*, 26:556-614 (Oct.), 1931.
18. Mills, Ralph G. Pulmonary Asbestosis. *Minnesota Medicine*, 13:495 (July), 1930.
19. Tattersall, Norman. The Occurrence and Clinical Manifestations of Silicosis among Hard-Ground Workers in Coal Mines. A paper read at the Bristol Congress.
20. Cummins, S. Lyle. Coal Miners and Tuberculosis. *J. State Med.*, 39:526-536 (Sept.), 1931.
21. McFarland, William. Silicosis and Tuberculosis as Seen in Granite Workers in Vermont. *J. Indust. Hyg.*, 9:315 (Aug.), 1927.
22. Russell, A. E., et al. II. Exposure to Siliceous Dust (Granite Industry). *Pub. Health Bull.* 187, 1929.
23. Head, Jerome R., and Rosenblum, Samuel H. Silicosis in a Tuberculosis Hospital. *J.A.M.A.*, 99:915 (Sept. 10), 1932.
24. Lemon, William S., and Higgins, George M. Pulmonary Fibrosis: Experiments of Short Duration. *Am. J. Med. Sci.*, 719:153-164 (Feb.), 1932.
25. Belt, T. H. Pathology of Silicosis of the Lung. *Canad. Pub. Health J.*, 20:494-508 (Oct.), 1929.
26. Arntzen, J. S. Pneumoconiosis. *U. S. Vet. Hosp. Bull.*, 5:31-35 (Jan.), 1929.
27. McNally, W. D. Pneumoconiosis—Silicon Dioxide Content of Lungs in Health and Disease. *J.A.M.A.*, 101:584-587 (Aug. 19), 1933.
28. Gardner, Leroy V. Pneumoconiosis, Pathology of So-Called "Acute" Silicosis. *A.J.P.H.*, 23:1240-1249 (Dec.), 1933.
29. Pancoast, Henry K., and Pendergrass, Eugene P. Pneumoconiosis, Roentgenological Aspect of and Its Differential Diagnosis. *J.A.M.A.*, 101:587-593 (Aug. 9), 1933.
30. Lemon and Feldman. Pneumoconiosis—Silicosis and Tuberculosis. *Arch. Int. Med.*, 53:367-378 (Mar.), 1934.
31. Sappington, C. O. Pneumoconiosis, Silicosis and other Dust Diseases. *Indust. Med.*, 1:158-168 (Dec.), 1932; *Abst. Surg., Gyn., Obs.*, 56:546-547 (Feb.), No. 2a, 1933.
32. Todhunter, J. R., and Dixon, G. B. Pneumoconiosis. *Lancet*, 2:1123 (Nov. 19), 1932.
33. Sayers, R. R. Pneumoconiosis, Silicosis. *Pub. Health Rep.*, 49:595-603 (May 18), 1934.

## League of Mental Hygiene in Brazil

THE National League of Mental Hygiene of Brazil, according to its recent report, has been giving most of its attention in the 10 years of its existence to a campaign against alcoholism, to physical examination of persons intending to marry, particularly men, and to child guidance work. The child guidance clinic established by the league is working with mentally retarded or

otherwise mentally abnormal children in some of the public schools of Rio de Janeiro. Each child is given a thorough physical and psychological examination, and a written report of his condition with the necessary advice is presented to the parents. The results of this work are highly praised in Brazil.—*Archivos Brasileiros de Hygiene Mental*, Rio de Janeiro, 6, 4, 1933.